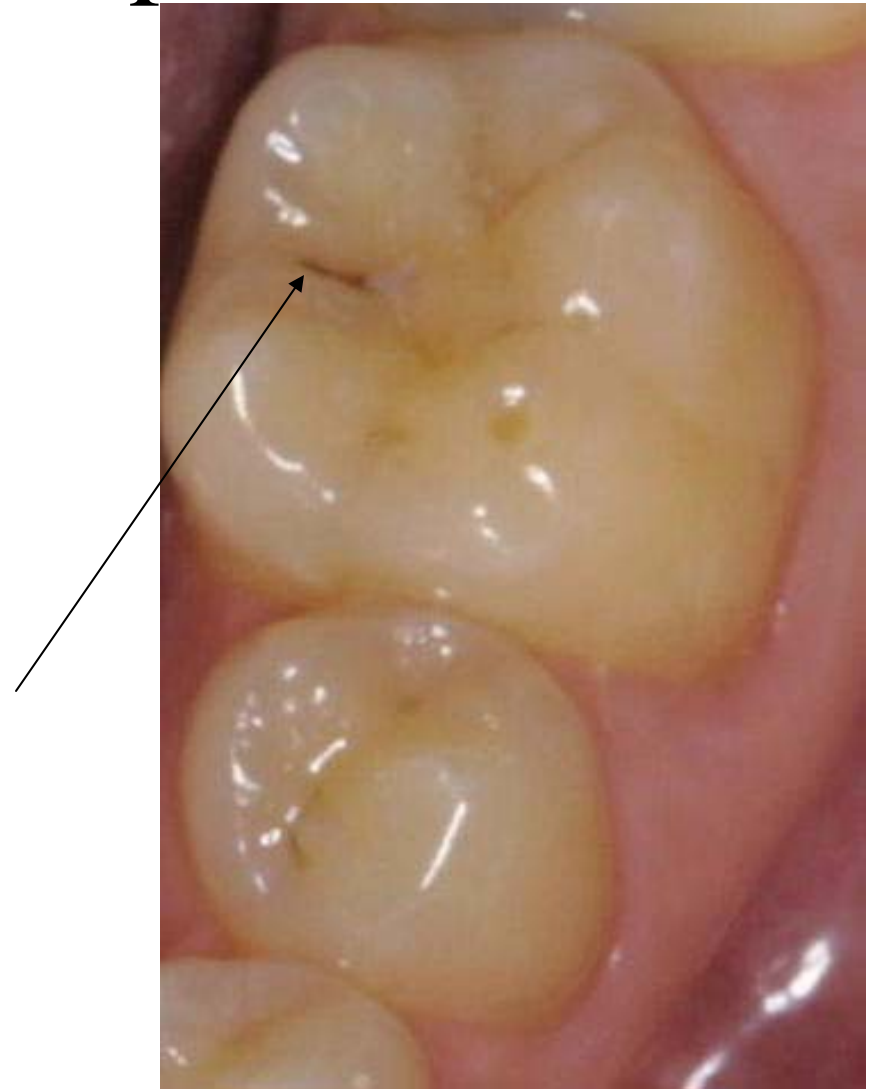
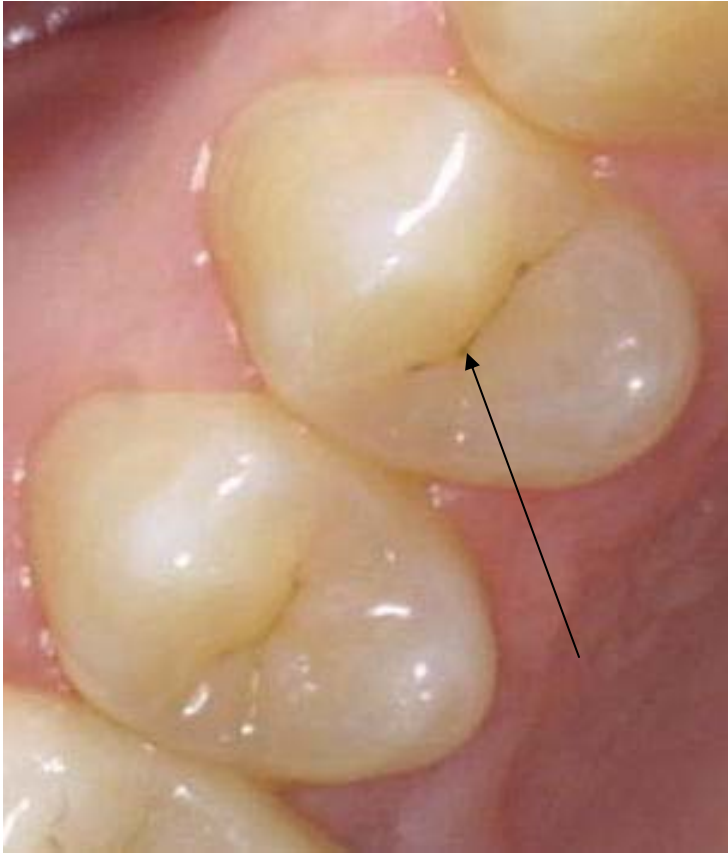
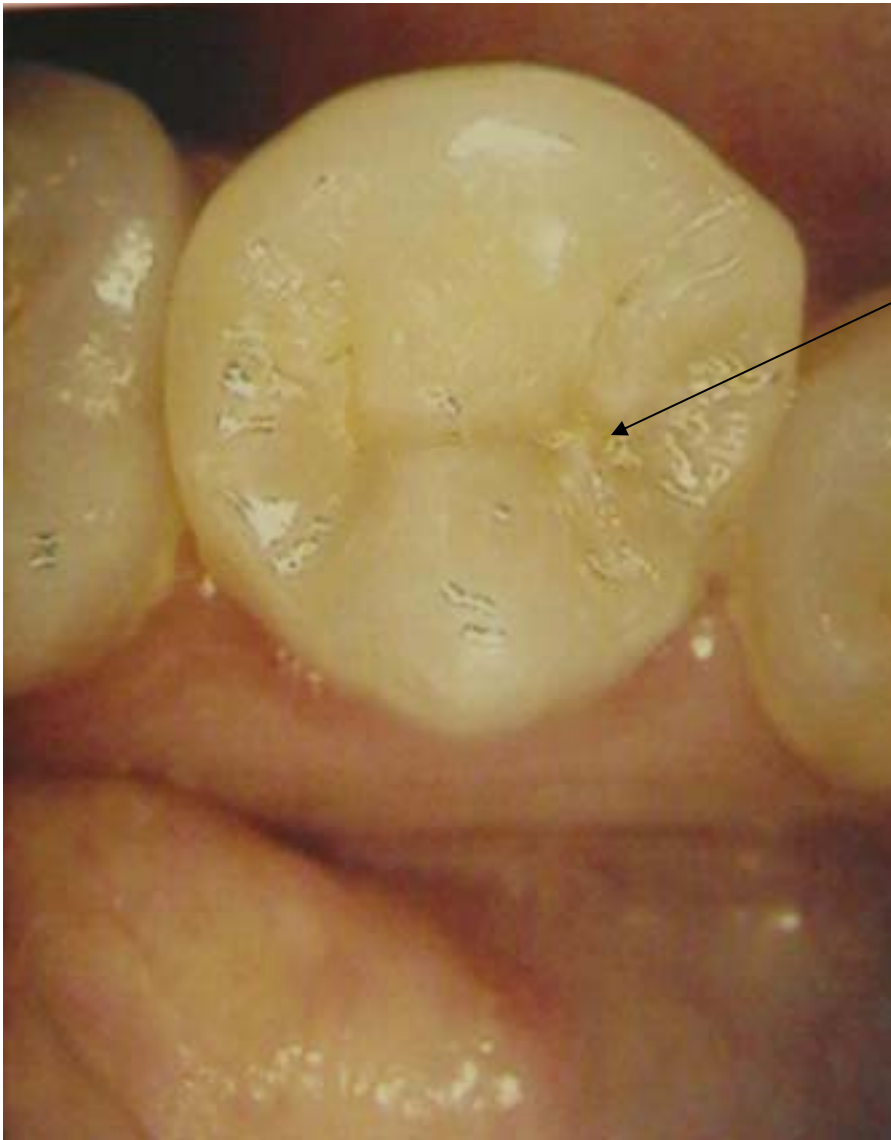
Decays that seem small may hide more serious problems

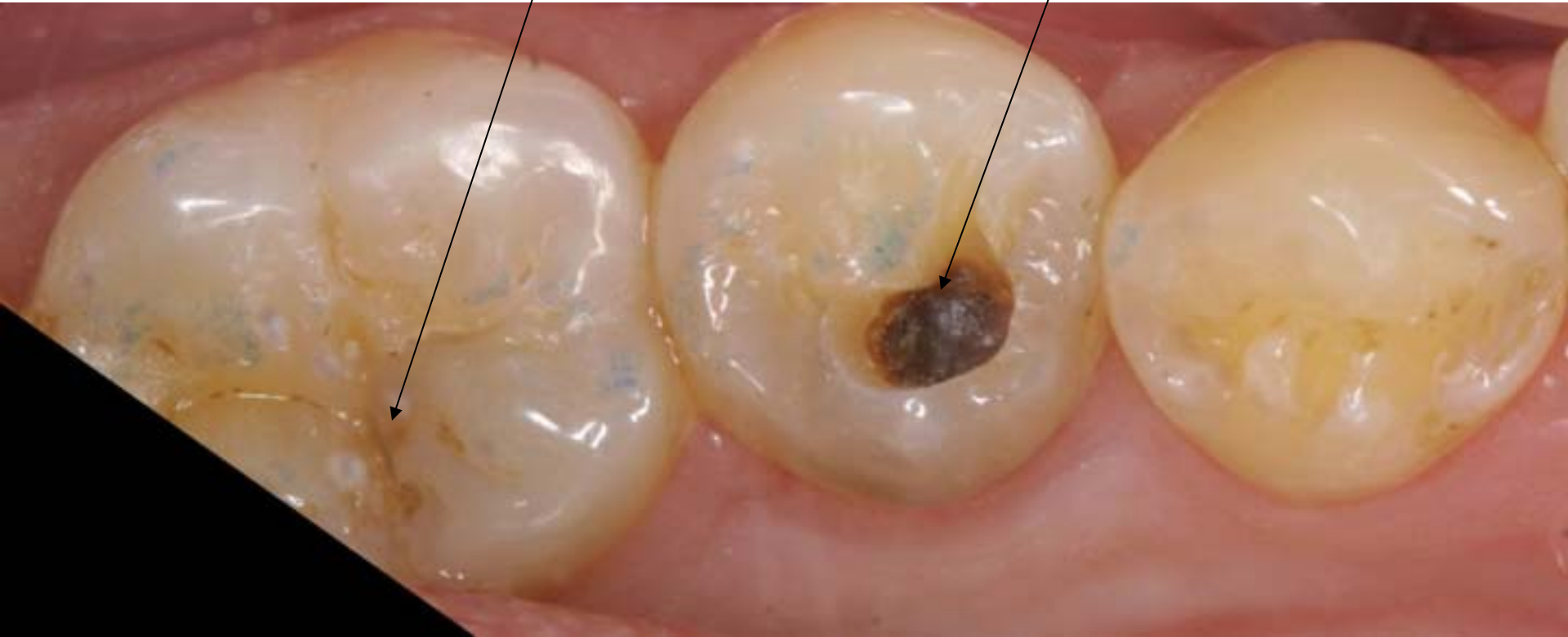



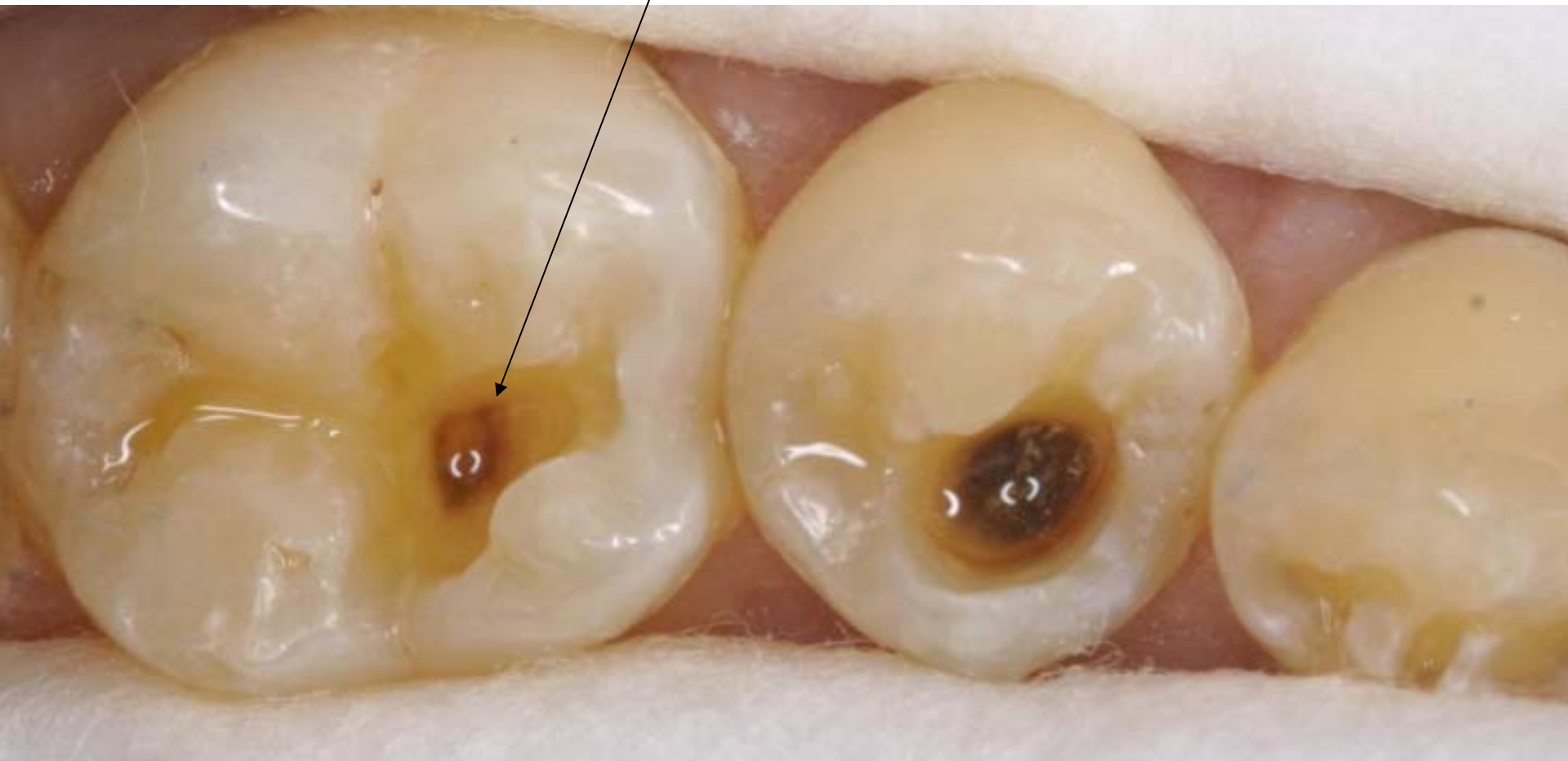The decay in this example seemed minimal.

If we were still using explorers (the metal hook) to check for “cavities that stick”, this would not have been diagnosed as a decay at all.

Keep an eye on the molar. I almost did not include it in the picture because it looked like just a stain. Watch what happens...



When the decay was removed it proved to be much more extensive, nearing the nerve. It would have soon needed root canal therapy.



The molar tooth also had a deeper decay than could have been foreseen based on outside appearance

Conclusions:

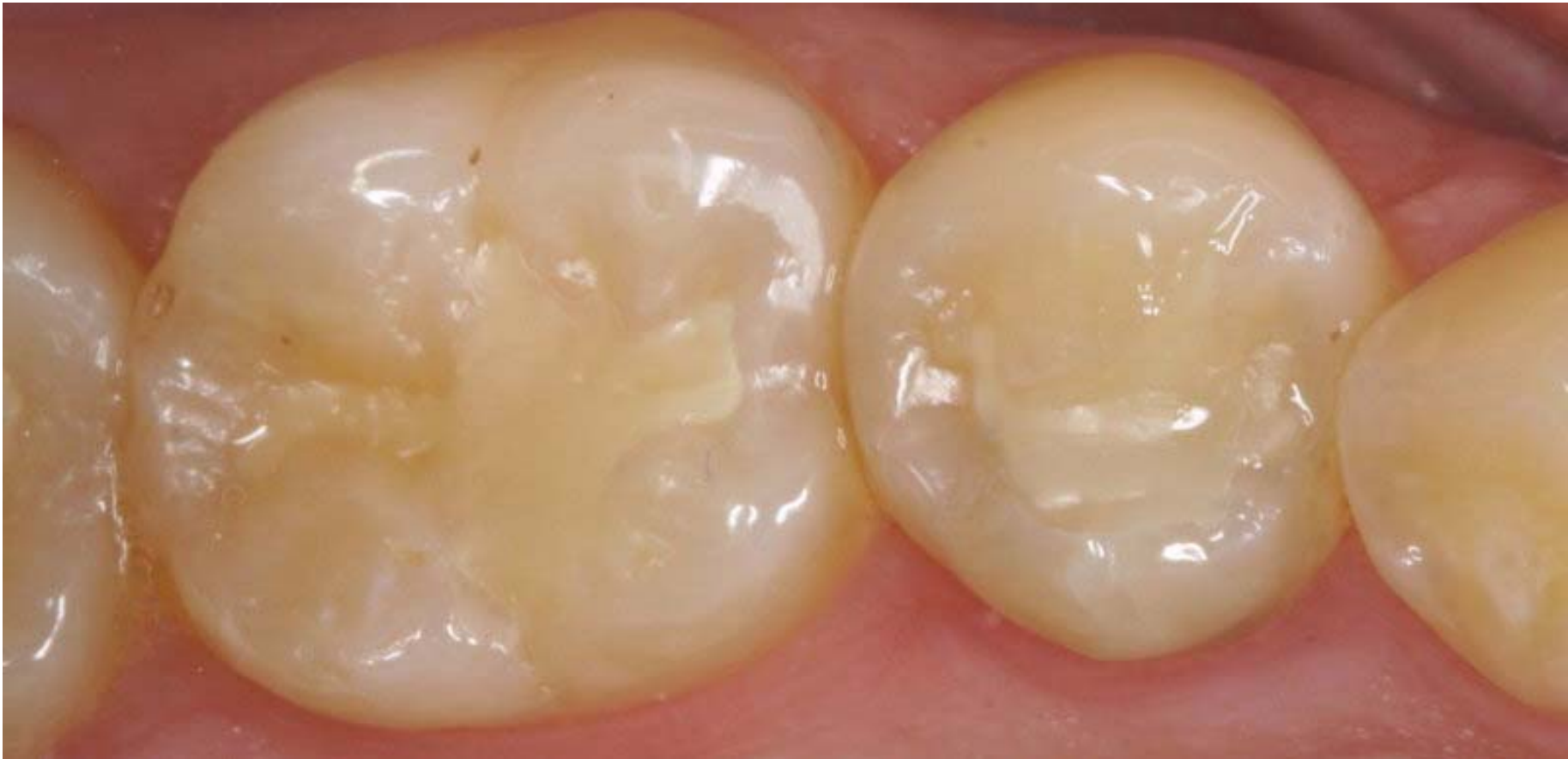Diagnosing cavities with Explorers alone misses 3 out of 4 decays.

Intra oral camera and diagnostic lasers are better devices to catch decays early.

To prevent decays destroying any **more** tooth and possibly reaching the nerve to cause an abscess (and the associated cost of a root canal therapy, buildup and a porcelain onlay – about \$2000.00), I recommend a pro-active approach.

Where possible, repair the decays with bonded direct composites (instead of Mercury fillings) as soon as possible.

Six months after being restored with bonded composite restorations



If there is inadequate tooth left to support a composite, repair with bonded indirect (custom made in a dental lab) All Porcelain Empress Onlays (instead of crowns)